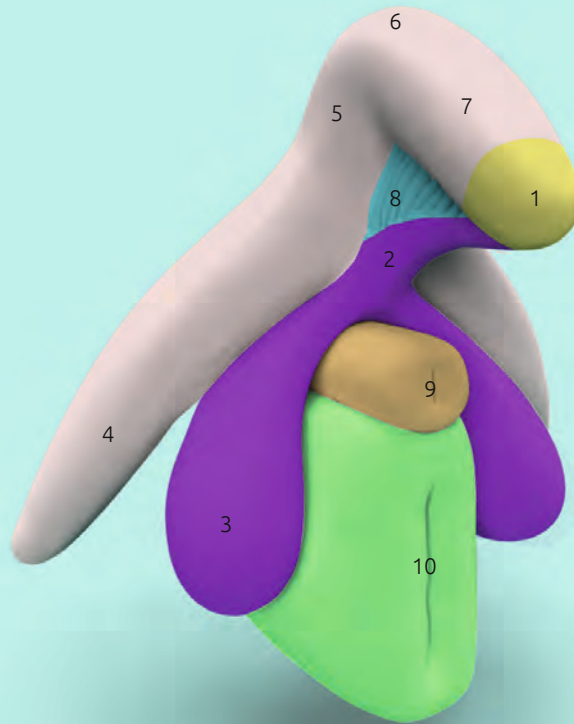


# Clitoris Plus Model

Prof. Dr. D. Haag-Wackernagel



## Beschreibung

- 1 Glans of clitoris *Glans clitoridis*
- 2 RSP (Infra-corporeal Residual Spongy Part)
- 3 Bulb of vestibule *Bulbus vestibuli*
- 4 Crus of clitoris *Crus clitoridis*
- 5 Body of clitoris ascending part  
*Corpus clitoridis pars ascendens*
- 6 Angle of the clitoral body
- 7 Body of clitoris descending part  
*Corpus clitoridis pars descendens*
- 8 Intermediate Network of Kobelt  
*Pars intermedia*
- 9 Urethra *Urethra feminina*
- 10 Vagina *Vagina*

The model „Clitoris Plus“ consists of two parts, the bulbo-clitoral-organ (1–8) named after Di Marino & Lepidi (2014) and the urethra (9) with the underlying vagina (10).

The organ commonly referred to as the clitoris consists of various structures with differing characteristics and embryonic origin. The erectile cavernous bodies consist of a complex network of venous sinuses and a thick fibrous envelope, the tunica albuginea, enabling these bodies to fill with blood, increase in size and harden. It is formed by the crus of clitoris (4) that merges into the ascending clitoral body (5), the clitoral angle (6) and the descending clitoral body (7). The cavernous structures show a high density of sensory nerve endings, called genital or bulbous corpuscles and Pacinian corpuscles. These corpuscles perceive tactile stimuli that are translated by the central nervous system into sensations of sexual excitement.

The spongy structures (corpus spongiosum) of the bulbo-clitoral organ include the glans of clitoris (1), the RSP (2) the vestibular bulbs (3), and the intermediate network of Kobelt, the pars intermedia (8). The only structure visible from the outside is the glans of clitoris, a cap-like formation on the tapered ends of the descending clitoral body. With its approximately 8,000 sensory nerve endings it is one of the most sensitive structures of the human body. It is exclusively dedicated to female sexual pleasure. Due to its embryonic origin, it is connected to the vestibular bulbs via the RSP.

The vestibular bulbs (3) „ride“ on the urethra (9) and the underlying vagina (10). They also consist of cavernous tissue but due to the absence of a true tunica albuginea and a sub-albugineal venous network, an erection is not possible.

The intermediate Network of Kobelt or pars intermedia (8) can be regarded

ed as a blood distributor that connects the vascular structures of the bulbo-clitoral organ. Further venous connections from the pars intermedia exist to the labia minora, the clitoral frenulum, the vestibule, and the vascular tissue of the urethra (9) and the vagina. The vagina (10) itself is only sparsely innervated and, as Kobelt already stated in 1844, should play no role in the generation of female sexual pleasure. During excitement the blood vessels of the vagina engorge with blood and secrete plasma as a lubricant protecting the vaginal tissue from injury.

During sexual arousal arterial blood flow increases and simultaneously, the smooth muscle fibers of the vascular sinuses relax, allowing them to engorge with blood. The resultant increased volume presses the sub-albugineal venous network against the tunica albuginea, blocking the drainage of blood and inducing a firming of the clitoral tissue. This leads to the

# Clitoris Plus Modell

Prof. Dr. D. Haag-Wackernagel

elevation of the clitoral body and the protrusion of the clitoral shaft from the clitoral hood. When pressure is exerted on the vestibular bulbs (3) and the crus of clitoris (4), e.g. by the thrusting of the penis or the reflexive contractions of the muscles that surround these structures, blood is forced into the clitoral body and the clitoral glans via the pars intermedia. The increase in pressure leads to a lowering of the sensory receptor activation threshold and a consequent activation of the numerous sensory nerve endings (genital corpuscles and corpuscles of Pacini) dedicated to generating sexual excitation, which ultimately leads to orgasm.

Maintaining the integrity of the external genitalia is therefore of the utmost importance for female sexual health!

---

## Literature

Di Marino V & Lepidi H (2014). Anatomic Study of the Clitoris and the Bulbo-Clitoral Organ. 152 pp. Springer International Publishing Switzerland

Kobelt G L (1844) Die männlichen und weiblichen Wollustorgane des Menschen und einiger Säugethiere in anatomisch-physiologischer Beziehung (The male and female lust organs of humans and some mammals in anatomical-physiological relation). Freiburg im Breisgau, Druck und Verlag von Adolph Emmerling.

## Acknowledgement

I thank Prof. Dr. med. Vincent Di Marino (University of Aix-Marseille, Medical Faculty) for his valuable support.

## Model

Prof. Dr. Daniel Haag-Wackernagel, Professor emeritus for Biology in Medicine, University of Basel

## Design

Amos Haag

## Contact

haag@wackernagel.ch

## Manufacturer

KESSEL medintim GmbH  
Kelsterbacher Str. 28  
64546 Mörfelden-Walldorf  
Germany

**EAN** 4013273002202

**Art.-No.** MO CLIT